



[Urol Case Rep](#), 2015 May; 3(3): 56–58.

Published online 2015 Mar 14. doi: [10.1016/j.eur.2015.01.011](https://doi.org/10.1016/j.eur.2015.01.011)

PMCID: PMC4714265

## Iatrogenic Extraprostatic Extension of Prostate Cancer From a Needle Biopsy

Michael H. Johnson, Francesca Khanj, and Edward M. Schaeffer

Johns Hopkins Medical Institutions, Brady Urological Institute, 600 N Wolfe St, Baltimore, MD 21287, USA

Michael H. Johnson: [michael.h.johnson@jhmi.edu](mailto:michael.h.johnson@jhmi.edu)

\*Corresponding author. Tel.: +1 4432870240 [michael.h.johnson@jhmi.edu](mailto:michael.h.johnson@jhmi.edu)

Received 2015 Jan 19; Accepted 2015 Jan 27.

Copyright © 2015 The Authors

This is an open access article under the CC BY-NC-ND license (<http://creativecommons.org/licenses/by-nc-nd/4.0/>).

### Abstract

[Go to](#)

Seeding of prostate cancer along a needle biopsy track is a rare complication. The diagnosis of this presents a significant upstaging of the disease and profound potential changes to the treatment strategy. In this report, we present a 71 year-old male with otherwise low-risk prostate cancer on final pathology except for extraprostatic extension (EPE) along a probable needle track. We further review the relevant literature regarding this rare but important complication with prostate needle biopsy.

**Keywords:** Prostate cancer, Biopsy, Extraprostatic extension

### Introduction

[Go to:](#)

Transrectal ultrasound-guided needle biopsy of the prostate (TRUS-Bx) is a frequently performed procedure to diagnose prostate cancer. While rare, it is possible that prostate cancer cells can be displaced extraprostatically by the biopsy needle and subsequently proliferate. This iatrogenically-induced extraprostatic extensions can cause a diagnostic dilemma regarding adjuvant treatment. In this report, we present a patient with low-risk prostate cancer who was found to have a single focus of extraprostatic extension along a needle biopsy track.

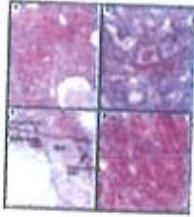
### Case presentation

[Go to:](#)

A 71 year old male was referred to our institution in 2008 for management of prostate cancer after a single microscopic focus of Gleason 3 + 3 = 6 prostate cancer was found on TRUS-Bx. At the time, he had 3 prior negative prostate biopsies, his PSA was 2.7 ng/ml, and 14.7% free PSA. He was placed on expectant management and, in 2014, he underwent a prostate biopsy showing one core of Gleason 3 + 4 = 7 involving 30% with perineural invasion. He elected for radical retropubic prostatectomy with bilateral pelvic lymphadenectomy. His postoperative course was unremarkable.

On final pathology, his prostate was 97.9 g, with no palpable nodules. There was a dominant tumor nodule of Gleason score 3 + 3 = 6 involving the right posterolateral region, extending from the apex to the mid portion of the gland (Fig. 1A and B). The tumor comprised approximately 1–2% of the total prostate gland volume. There was a focal area of extraprostatic extension (EPE) identified in a probable area of needle tract displacement in the right posterior mid gland. Biopsy-site changes with a fibrotic scar and hemosiderin-laden macrophages were present in the area of EPE (Fig. 1C and D). No seminal

vesicle invasion by tumor was present, and all margins were negative. In a bilateral pelvic lymphadenectomy, all six lymph nodes were negative for tumor. The prostate cancer was staged as a pT3a N0 with a note indicating that the area of EPE was due to displaced carcinoma involving a needle tract.



**Figure 1**

Radical prostatectomy specimen with prostatic adenocarcinoma, Gleason score  $3 + 3 = 6$  shown in (A) with infiltrative well-formed small glands and adjacent benign atrophic prostatic glands. At higher power (B), the tumor glands show abundant amphophilic ...

## Discussion

[Go to](#)

Approximately 1 million prostate biopsies are performed annually as a means of prostate cancer diagnosis or surveillance.<sup>1</sup> Tumor seeding along the biopsy tract is a very rare but nonetheless reported risk.<sup>2</sup> Bastacky et al reviewed a series of 350 prostatectomy specimens from the Johns Hopkins Hospital, assessing for extension of disease along a needle biopsy track. In this series, the authors reported a 2% incidence of tracking, with an additional 3.7% being equivocally positive for extension along the needle track.<sup>3</sup> Volanis et al recently published a literature review of needle track seeding during TRUS-Bx and identified 42 reported cases.<sup>4</sup> The majority of these were older case reports using transperineal biopsy and, unlike the patient in this report, the majority involved poorly differentiated adenocarcinoma. Diagnosis was made by biochemical recurrence, palpable nodule on DRE, perineal mass, and incidental finding during colorectal surgery. The reported time to disease recurrence was variable, from 1 month to 14 years. Unfortunately, many of the diagnoses of cancer tracking via needle biopsy were deduced from post-prostatectomy recurrence rather than by diagnosis of the prostate at time of surgical extirpation.

The rarity of tumor seeding along a biopsy track makes it difficult to identify risk factors. Needle type or size, biopsy approach (transrectal vs. transperineal), or biopsy technique fail to show any increased associated risk. Indeed, the number of biopsies needed to statistically identify risk factors is prohibitively large. Although outside the scope of this report, tumor seeding from prior tissue sampling has been reported in many malignancies, genitourinary and otherwise.

The implication of tumor seeding along the needle track is potential upstaging of prostate cancer from stage I to stage III. Adjuvant radiation with or without hormonal therapy may be considered, as it reduces metastases and improves survival in a randomized trial of patients with pathologic T3 disease.<sup>5</sup> However, the must be counterbalanced with the side effects of incontinence and impotence. With isolated extension along a needle track and Gleason  $3 + 3 = 6$  disease, the reported patient opted for monitoring with early salvage therapy if he recurred biochemically. Four months postoperatively, he was continent, regaining erectile function, and PSA was undetectable.

## Conclusion

[Go to](#)

EPE of otherwise low-risk prostate adenocarcinoma along a needle biopsy track is a rare finding. Adjuvant treatments for EPE should be discussed with the patient, although the risks of adjuvant therapy may outweigh surveillance with early salvage therapy.

## Conflicts of interest

[Go to:](#)

None to report.

## Footnotes

[Go to:](#)



**References**

Go to:

1. Loeb S., Vellekoop A., Ahmed H.U. Systematic review of complications of prostate biopsy. *Eur Urol.* 2013 Dec;64(6):876–892. [[PubMed](#)]
2. Robertson E.G., Baxter G. Tumour seeding following percutaneous needle biopsy: the real story! *Clin Radiol.* 2011 Nov;66(11):1007–1014. [[PubMed](#)]
3. Bastacky S.S., Walsh P.C., Epstein J.I. Needle biopsy associated tumor tracking of adenocarcinoma of the prostate. *J Urol.* 1991 May;145(5):1003–1007. [[PubMed](#)]
4. Volanis D., Neal D., Warren A. Incidence of needle-tract seeding following prostate biopsy for suspected cancer: a review of the literature. *BJU Int.* 2014 Jun 23 Epub. [[PubMed](#)]
5. Thompson I.M., Tangen C.M., Paradelo J. Adjuvant radiotherapy for pathological T3N0M0 prostate cancer significantly reduces risk of metastases and improves survival: long-term followup of a randomized clinical trial. *J Urol.* 2009 Mar;181(3):956–962. [[PubMed](#)]

---

Articles from Urology Case Reports are provided here courtesy of **Elsevier**